

Novel paediatric presentation of COVID-19 with ARDS and cytokine storm syndrome without respiratory symptoms



Lancet Rheumatol 2020

Published Online

May 15, 2020

[https://doi.org/10.1016/S2665-9913\(20\)30137-5](https://doi.org/10.1016/S2665-9913(20)30137-5)

Severe acute respiratory syndrome coronavirus 2 (SARS-CoV-2) is the pathogen that causes COVID-19. Although early studies suggested that children and adolescents could be spared from severe disease, reports have since been published of children hospitalised or dying from COVID-19.^{1,2} We report a 14-year-old previously healthy individual who presented to our institution with a 3-day history of pyrexia, abdominal pain, nausea, and vomiting, but without respiratory symptoms. The patient's mother reported mild respiratory symptoms 3 weeks previously but the patient had not been tested for SARS-CoV-2.

On admission (day -2), the patient was febrile (38.1°C) and cardiovascularly stable, and showed no signs of respiratory distress (figure). The abdomen was tense, with guarding in the right upper and lower quadrants. Initial investigations showed lymphopenia (0.14×10^9 cells per L [normal range 1.5–7.6]), a significant increase in C-reactive protein (242 mg/L [normal range 0–8]), and sterile pyuria (30 cells). The patient was started on empiric piperacillin–tazobactam for suspected acute appendicitis, and nasopharyngeal swabs were sent for SARS-CoV-2 PCR testing. Chest radiography (figure, A) and abdominal ultrasound were normal. Within 24 h of admission, the patient developed increasing dyspnoea, cough, and oxygen requirement (8 L/min), finally escalating to continuous positive airway pressure ventilation support. The patient seemed visually more unwell and interacted less, developed a widespread maculopapular blanching rash (figure, B), and received fluid boluses for persistent tachycardia. Chest CT showed typical findings of SARS-CoV-2 pneumonia (figure, C).³ A diagnosis of presumptive COVID-19 was made. Secondary multi-system inflammatory disease or cytokine storm syndrome was diagnosed based on clinical symptoms, lymphopenia, anaemia, thrombocytopenia, increased acute-phase proteins (ie, C-reactive protein and ferritin), raised serum interleukin (IL)-6 (1098 pg/mL [normal range <7]), coagulopathy (D-dimer >4810 ng/mL [normal range <500]), prothrombin time 16.2 s [normal range 9.8–11.4], and activated partial thromboplastin time 43.4 s [normal range 24.2–30.2]), increased liver enzymes (aspartate aminotransferase 166 IU/L [normal range <37] and alanine aminotransferase 156 IU/L [normal

range <40]), and hypertriglyceridaemia (2.3 mmol/L [normal range 0.4–1.4]). Antinuclear antibodies tested negative. Antiphospholipid antibodies (anticardiolipin IgG 25.5 U/mL [normal range <20] and antiβ₂-glycoprotein IgG 28.8 U/mL [normal range <20]) were positive, and serum complement levels were pathologically low (C3 0.09 g/L [normal range 0.90–1.88], C4 0.12 g/L [normal range 0.18–0.42]). Furthermore, the patient developed mild polyarticular arthritis of the small joints of the hands. No substantial cervical lymphadenopathy, conjunctivitis, or mucous membrane changes were seen to suggest classic or complete Kawasaki disease.

The patient was not eligible for remdesivir compassionate use because SARS-CoV-2 PCR was negative. Because the patient showed clinical features suggestive of COVID-19-associated cytokine storm syndrome,^{1,4} anti-inflammatory treatment with recombinant IL-1 receptor antagonist (anakinra) was initiated after multidisciplinary discussions. Anakinra was started at 4 mg/kg per day (100 mg twice a day) subcutaneously and increased to 8 mg/kg per day (200 mg twice a day) after 36 h, because the patient required inotropic support for hypotension and rising lactate (6 mmol/L). Borderline left-ventricular systolic dysfunction, enzyme leak (troponin-T 45 ng/L), aortic regurgitation, and progressive left coronary dilatation were noted (figure, D), and aspirin was started (2 mg/kg) for its antithrombotic effects. Of note, Kawasaki disease-like features, including coronary aneurysms, have been reported in patients with COVID-19.² Since coronary artery dilation can occur in the context of systemic inflammatory disease, endothelial activation, or both,⁵ and because the patient did not show additional clinical features of Kawasaki disease, we did not start intravenous immunoglobulin or corticosteroids, after weighing the risks associated with intravenous immunoglobulin treatment (ie, thromboembolic events, aseptic meningitis, and antibody-dependent enhancement).

In temporal relation with anakinra treatment, the patient's respiratory status stabilised and clinical and laboratory variables returned to normal (figure, E), with the exception of coronary dilation that persisted at the time of discharge. Thus, anakinra was tapered and discontinued after 6 days. Subsequently, serum tested positive for

SARS-CoV-2 IgG (borderline day 6, positive day 11). SARS-CoV-2 PCR on three nasopharyngeal samples (days 3, 5, and 7) and stool (day 11) were negative.

To our knowledge, this case is the first paediatric patient reported with cytokine storm syndrome during the COVID-19 pandemic presenting without respiratory symptoms on hospital admission who was successfully treated with IL-1 inhibition. Although respiratory and stool PCR testing was negative, CT chest findings and biochemical and haematological variables were highly suggestive of COVID-19, with evidence of seroconversion. Considering that PCR test sensitivity ranges around 60%, after three negative PCR results, this case could represent a post-COVID-19 inflammatory process. An alternative explanation could be viral replication at an alternative site. Although the patient developed early-stage acute respiratory distress syndrome (ARDS) in the hospital (severe oxygenation defect and bilateral pulmonary infiltrates), respiratory symptoms were not part of the initial presentation. Thus, the case resembles a previously unappreciated clinical phenotype of COVID-19 in children with rapid onset ARDS and cytokine storm syndrome after fever and abdominal pain in the absence of preceding respiratory symptoms.^{1,2}

Based on our current pathophysiological understanding, SARS-CoV-2 replicates in respiratory and intestinal epithelial cells and suppresses early type I interferon responses. Furthermore, SARS-CoV-2 can abortively infect innate immune cells (monocytes and macrophages), which can be facilitated by immune complexes, accelerating viral replication and amplifying proinflammatory cytokine (IL-1, IL-6, tumour necrosis factor [TNF]) release in a process termed antibody-dependent enhancement. Viral replication results in tissue damage and excessive recruitment of innate and adaptive immune cells, which mediates a dysregulated hyperinflammatory response

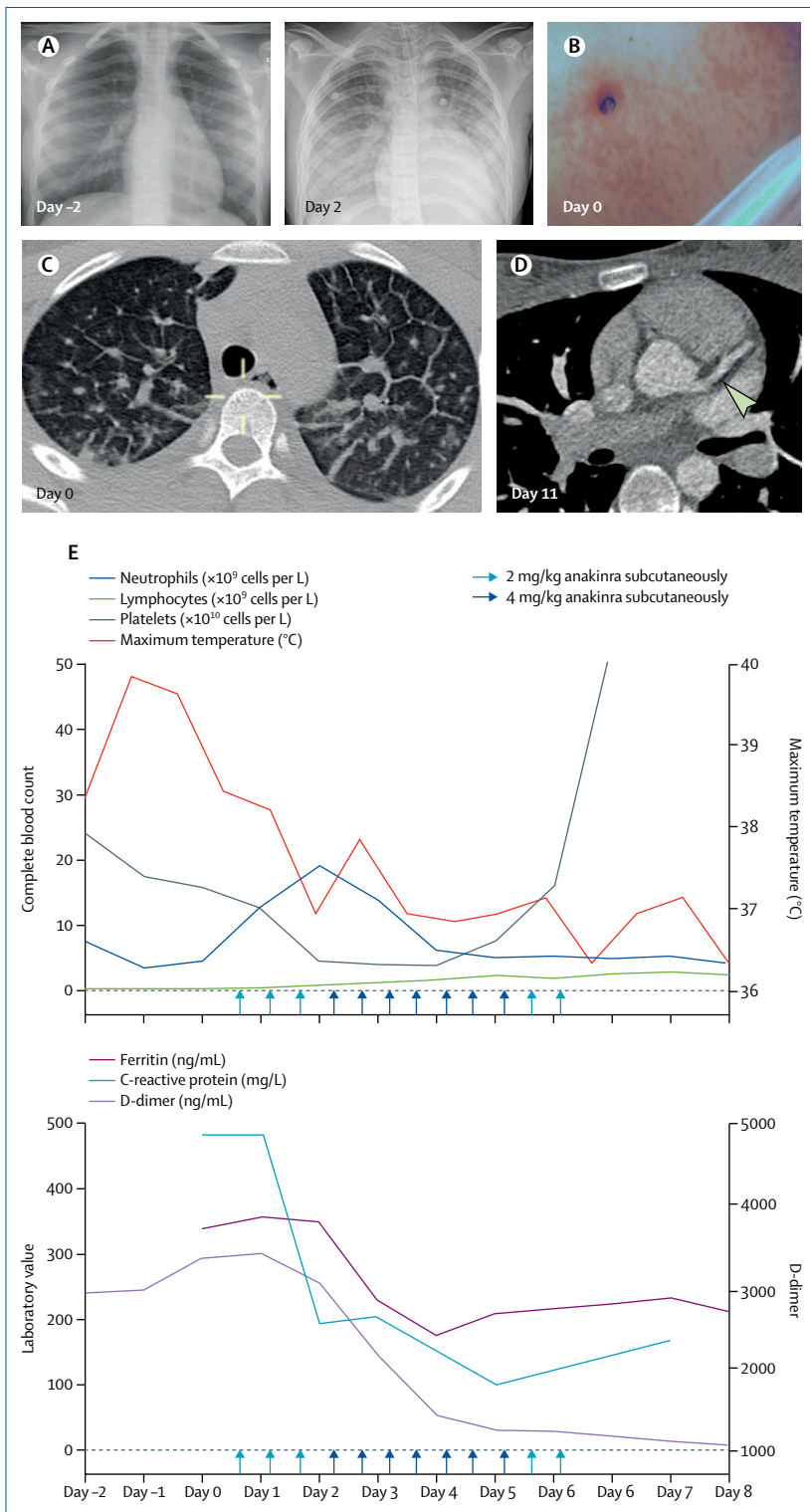


Figure: Clinical findings in a 14-year-old patient with COVID-19 and cytokine storm syndrome

Although chest radiography was normal at admission (day -2; A, left panel), follow-up imaging 4 days later (A, right panel) showed dense infiltrates suggestive of early-stage acute respiratory distress syndrome in the context of COVID-19. A widespread maculopapular blanching rash (B) appeared on the second day after admission (day 0) and improved after initiation of anakinra treatment. Axial CT on day 0 (C), when anakinra treatment was started, shows interlobular and intralobular septal thickening and rounded ground-glass opacities, predominantly in a peripheral distribution in both lungs; small peripheral or subpleural areas of subsegmental collapse or consolidation are noted, particularly at the bases. Axial CT on day 11 (D) shows a severely dilated left mainstem coronary artery (arrow) and proximal left anterior descending artery (Z-score 6.6 on echocardiography [not shown] and CT). Laboratory and clinical (core temperature) variables (E) indicate rapid and sustained improvement temporally associated with anakinra treatment (started day 0).

that contributes to cytokine storm syndrome and organ damage, including ARDS.⁶ In addition to the direct cytopathic effect inflicted on target organs, pulmonary damage seen in COVID-19 is probably augmented, if not dominated, by an unopposed dysregulated immune response. ARDS can occur in patients with primary or secondary cytokine storm syndrome, including systemic juvenile idiopathic arthritis, resembling the clinical picture in the reported patient. This finding could account for the rapid onset of clinical and imaging findings.⁷ Since the patient showed altered clotting (prolonged prothrombin time and activated partial thromboplastin time, and increased D-dimer) in the presence of antiphospholipid antibodies and pathologically reduced serum complement levels, immune complex generation and deposition could, in addition to endothelial activation through IL-1, have contributed to activation of the complement and clotting cascades.⁸ Indeed, post-infectious antiphospholipid syndrome with thromboembolism has been reported in the context of COVID-19.⁹ Furthermore, complement activation can take place in systemic inflammatory disorders, such as systemic juvenile idiopathic arthritis-associated macrophage activation syndrome.¹⁰

Off-label treatment with anakinra was chosen to limit proinflammatory cytokine expression, which could have been triggered by antibody-dependent enhancement or invasion of yet uninfected immune cells to infected tissues. Of note, anakinra blocks IL-1 receptor signalling, which induces the expression of IL-1, IL-6, and TNF via activation of NF- κ B-dependent pathways.¹¹ Although most clinical trials currently underway investigate IL-6 blockade, we chose anakinra based on its action upstream of IL-6 and because of less neutropenia, liver enzyme elevation, and hypertriglyceridemia, which are already present in patients with cytokine storm syndrome. Furthermore, anakinra reduces mortality in sepsis patients,¹² whereas chronic use of IL-6 blocking agents might increase the risk of secondary infections. Anakinra treatment coincided with clinical improvement and was stopped after 6 days.

During the ongoing pandemic, COVID-19 must be considered in patients with increased inflammatory variables and abdominal symptoms. The onset of cytokine storm syndrome and ARDS can be rapid and life-threatening. Based on the time of testing, the site of infection, or both, PCR testing might remain negative.

Anakinra is safe and effective in other inflammatory and autoinflammatory disorders, and it could be beneficial in COVID-19-associated cytokine storm syndrome, in which disordered host responses contribute to pathology. Inflammatory endothelial activation, antiphospholipid antibodies, and complement activation all promote a proinflammatory and coagulopathic state. Antithrombotic prophylaxis should be considered, particularly in the presence of coronary artery dilation or aneurysm. Prospective controlled trials are necessary to generate evidence for stage-specific and individualised treatment options in COVID-19.

We declare no competing interests. CEP and SF, and DP and CMH, contributed equally. The patient's mother provided consent to publish this case report.

Clare E Pain, Susanna Felsenstein, Gavin Cleary, Sarah Mayell, Karsten Conrad, Srikrishna Harave, Phuoc Duong, Ian Sinha, David Porter, *Christian M Hedrich
christian.hedrich@liverpool.ac.uk

Department of Rheumatology (CEP, GC, CMH), Department of Infectious Diseases and Immunology (SF, DP), Department of Respiratory Medicine (SM, IS), Department of Radiology (SH), and Department of Cardiology (PD), Alder Hey Children's NHS Foundation Trust Hospital, Liverpool, UK; Institute of Immunology, Medical Faculty "Carl Gustav Carus", Technical University of Dresden, Dresden, Germany (KC); and Department of Women's & Children's Health, Institute of Translational Medicine, University of Liverpool, Liverpool L69 3BX, UK (CMH)

- Hedrich CM. COVID-19: considerations for the paediatric rheumatologist. *Clin Immunol* 2020; **214**: 108420.
- Riphagen S, Gomez X, Gonzalez-Martinez C, Wilkinson N, Theocharis P. Hyperinflammatory shock in children during COVID-19 pandemic. *Lancet* 2020; published online May 7. [https://doi.org/10.1016/S0140-6736\(20\)31094-1](https://doi.org/10.1016/S0140-6736(20)31094-1).
- Chen H, Ai L, Lu H, Li H. Clinical and imaging features of COVID-19. *Radiol Infect Dis* 2020; published online April 27. DOI:10.1016/j.jrid.2020.04.003.
- Henderson LA, Canna SW, Schuler GS, et al. On the alert for cytokine storm: immunopathology in COVID-19. *Arthritis Rheumatol* 2020; published online April 15. DOI:10.1002/art.41285.
- Muniz JC, Dummer K, Gauvreau K, Colan SD, Fulton DR, Newburger JW. Coronary artery dimensions in febrile children without Kawasaki disease. *Circ Cardiovasc Imaging* 2013; **6**: 239–44.
- Felsenstein S, Herbert JA, McNamara PS, Hedrich CM. COVID-19: immunology and treatment options. *Clin Immunol* 2020; **215**: 108448.
- Kessel C, Hedrich CM, Foell D. Innately adaptive or truly autoimmune: is there something unique about systemic juvenile idiopathic arthritis? *Arthritis Rheumatol* 2020; **72**: 210–19.
- Chanchal S, Mishra A, Singh MK, Ashraf MZ. Understanding inflammatory responses in the manifestation of prothrombotic phenotypes. *Front Cell Dev Biol* 2020; **8**: 73.
- Zhang Y, Xiao M, Zhang S, et al. Coagulopathy and antiphospholipid antibodies in patients with Covid-19. *N Engl J Med* 2020; **382**: e38.
- Gorelik M, Torok KS, Kietz DA, Hirsch R. Hypocomplementemia associated with macrophage activation syndrome in systemic juvenile idiopathic arthritis and adult onset Still's disease: 3 cases. *J Rheumatol* 2011; **38**: 396–97.
- Bruck N, Schnabel A, Hedrich CM. Current understanding of the pathophysiology of systemic juvenile idiopathic arthritis (sJIA) and target-directed therapeutic approaches. *Clin Immunol* 2015; **159**: 72–83.
- Shakoory B, Carcillo JA, Chatham WW, et al. Interleukin-1 receptor blockade is associated with reduced mortality in sepsis patients with features of macrophage activation syndrome: reanalysis of a prior phase III trial. *Crit Care Med* 2016; **44**: 275–81.